

Femtosecond laser shows promise for penetrating keratoplasty procedures

**Dermot McGrath
in Monte Carlo**

USING a Femtec femtosecond laser (20/10 Perfect Vision, Heidelberg, Germany) provides a safe, predictable and effective means of performing the cut in penetrating keratoplasty (PK) procedures, according to Mark Tomalla MD.

“The procedure is suitable not only for treatment of transparent corneal tissue, but can also be used with extreme precision in scarred corneal tissue”

Mark Tomalla MD

Addressing delegates attending the first Cornea Day organised as part of this year's ESCRS Winter Refractive Meeting, Dr Tomalla, Duisberg, Germany, noted that using a femtosecond laser offers several advantages over traditional approaches to penetrating keratoplasty.

“The femtosecond cuts are performed from endothelium to epithelium and any desired transplant size can be selected. Furthermore, any cut configuration and angulation can be chosen, the cut quality is high and the prepared donor transplant nestles perfectly in the opened eye. Also, the surgery is performed under complete visual control and the procedure is suitable not only for treatment of transparent corneal tissue, but can also be used with extreme precision in scarred corneal tissue,” he said.

The femtosecond laser allows greater precision by using computer software to match the exact shape of the removed and donated tissue segments. It also appears to deliver consistently good visual outcomes and faster recovery times, he reported.

Dr Tomalla discussed the case of an 80-year-old woman who was treated using the PK and femtosecond laser combination

in July 2005. The patient had undergone several surgeries on her right eye in the past, including a vitrectomy and laser coagulation in 1981 and cataract surgery and IOL implantation in 1988.

Since 1999, Dr Tomalla said she had experienced pronounced corneal decompensation after vitrectomy with silicone oil filling and her vision was limited to light perception and hand movement. Her vision was 0.03 postoperatively after her first keratoplasty. In 2003, further corneal decompensation led to dense scarring to the limbus and her vision was limited to hand movement.

The result after re-transplantation using the femtosecond laser in July 2005 was very positive, reported Dr Tomalla. “We had a well-adapted cornea, a stable anterior chamber and the transplant was clear and without folds. Best-corrected visual acuity was 0.05 after one day postoperatively, 0.125 after one month and the same after six months.”

The surgical technique for PK using the femtosecond laser is relatively straightforward, explained Dr Tomalla.

“We are able to take a variable diameter for the donor cornea up to a maximum of 9.0mm. The donor cornea is then cut from the endothelium to the epithelium with a defined corneal curvature between donor and host cornea and a cutting angle of exactly 90 degrees. We had a very good high-precision cut and the entire preparation was performed under visual control.”

To carry out the trephination, the recipient diameter was cut identical to the host diameter, with trephination from endothelium to epithelium.

“The perforating keratoplasty can also be performed accurately in cloudy corneas and again there is total visual control during the surgery,” said Dr Tomalla.

Dr Tomalla said that the procedure results in a central cornea that is clear and compact. The smooth matching surfaces, the perfect donor-recipient fit and the clean, sharp graft-host interface produced by the femtosecond laser contributes to the impressive outcomes observed in some patients within a few months postoperatively.

In a separate presentation, Gerd

Auffarth MD, University of Heidelberg, Germany also reported a positive clinical experience using the Femtec femtosecond laser for penetrating keratoplasty procedures.

He noted that both the Femtec and Intralase femtosecond lasers are FDA approved and CE certified for use in corneal surgery. Dr Auffarth reported that donor and recipient corneal excisions were carried out using the femtosecond laser on five patients aged between 45 and 84 years. Patients presented with a range of pathologies such as granular corneal dystrophy, Fuchs' endothelial dystrophy, keratoconus and bullous keratopathy after cataract surgery.

All procedures were performed without any complications, reported Dr Auffarth. In all cases the donor cornea was first cut with the laser to create a donor button 8.0mm or 8.1mm diameter. The recipients' corneas were then lasered with a 7.8mm diameter cut. In all cases a complete perforating cut was achieved.

Histology of the donor and recipient specimen after the cuts were performed showing a straight, smooth cut without any abnormalities. Additionally the clinical diagnosis could be confirmed, added Dr Auffarth.

“Perforating keratoplasty using the Femtec femtosecond laser can be performed safely and accurately with precise cut quality”

Gerd Auffarth MD

“Perforating keratoplasty using the Femtec femtosecond laser can be performed safely and accurately with precise cut quality. I think in the long run this will be a very interesting technology, especially if we can go into detail and can use different shapes and types of incisions with this type of laser,” he concluded.


mark.tomalla@ejk.de
ga@uni-hd.de



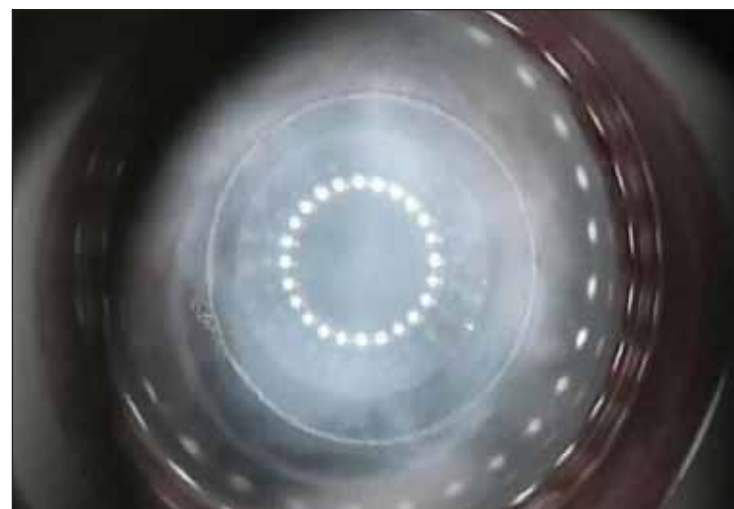
Gerd Auffarth



Mark Tomalla



Preparing donor cornea



Preparing recipient cornea

Courtesy of Mark Tomalla MD

